



Histochemical alterations in colorectal carcinoma and adenoma in Egyptian patients

Saber A Sakr^{1*}, Moshira M Abdel-Wahed², Asmaa G Abdou², Eman K El-Adely¹

¹Zoolgy Department, Faculty of Science, Menoufia University, Al Minufya, Egypt

²Pathology Department, Faculty of Medicine, Menoufia University, Al Minufya, Egypt

ARTICLE INFO

Article history:

Received 30 Oct 2015

Received in revised form 13 Nov, 2nd revised form 17 Nov 2015

Accepted 15 Dec 2015

Available online 22 Dec 2015

Keywords:

Colon cancer
Histochemistry
DNA
Carbohydrates

ABSTRACT

Objective: To evaluate the histochemical alterations in DNA and total carbohydrates, in colorectal cancer cells.

Methods: This study was carried out on 48 colorectal carcinoma and 10 adenoma specimens. Hematoxylin and Eosin staining was carried out for histopathological examination to confirm the diagnosis and to evaluate the histopathological characteristics of tumor. Histologic grade and pathologic stage was assessed according to TNM staging system. Staging was also assessed according to original Dukes' staging system. DNA was demonstrated by Feulgen method and carbohydrates were demonstrated by periodic acid Schiff's reaction.

Results: Adenoma cases showed that the cells lining the glands of the polyp have more crowded, irregular and darker nuclei (hyperchromatic), anisonucleosis, abnormal mitotic figures with prominent nucleoli and variability in the size and shape of nuclei. Colorectal carcinoma cases showed a condensation and reduction in the size of a cell nucleus associated with hyperchromatosis, pyknotic nuclei, abnormal mitotic figures, anisonucleosis, irregular nuclear membrane and inequality in the size of the nuclei (Pleomorphosis). There was a statistical significant differences between adenoma and carcinoma regarding number of mitotic cells ($P = 0.03$) that was in favour of malignant group. Adenoma and colorectal carcinoma cases showed periodic acid Schiff's reactivity with different degree.

Conclusions: These histochemical alterations can be so characteristic of a given tumor type and stage that they are used in cancer diagnosis and might also be related to the altered functional properties of cancer cells.

1. Introduction

Colorectal cancer (CRC) is a common cancer worldwide. It represents the third most common cause of cancer-related mortality and morbidity[1]. The epidemiology of CRC in developing countries differs from that of developed countries. Colorectal carcinoma in developing countries including Egypt is usually characterized by low incidence, young age of onset and left-sided location[2,3]. CRC was the 6th cancer in Egypt, representing 4% of the total cancers and 53% of gastrointestinal cancers. The median age was 53 years with male predominance. Colon cancers were more common than rectal cancers[4]. The high prevalence in young people can neither be explained on a hereditary basis nor can it be attributed to bilharziasis. Similarly, a study by Elbaz and Esmat[5] suggested that there was a strong relation between colon cancer and intestinal cancer in Egypt.

There are several risk factors which involved in pathogenesis of CRC such as personal history of CRC[5] older age[3], schistomiasis[6], environmental factors (diet, obesity, diabetes mellitus, alcohol,

smoking, physical activity and pesticides)[7].

Tumorigenesis appears as a multistep process not only in molecular terms but also in morphological alterations[8]. Among the observed changes in tumor cells are the histochemical alterations. These include changes in polysaccharides, proteins and nucleic acids. These alterations can be so characteristic of a given tumor type and stage that they are used in cancer diagnosis and might also be related to the altered functional properties of cancer cells[9]. The present work studied the histochemical changes in DNA and carbohydrates in colorectal carcinoma in Egyptian patients.

2. Materials and methods

2.1. Samples collection

This study was carried out on 58 colorectal specimens from Egyptian patients retrieved from Pathology Department, Faculty of Medicine, Menofiya University in the period between May 2007 and May 2011. The studied cases included 10 colorectal adenoma and 48 colorectal carcinoma. All studied adenoma cases were endoscopically resected mucosa or endoscopically resected polyps, however, all the studied carcinoma cases were surgically resected colectomy specimens. The study met the criteria of the Ethics Committee of the Institution.

*Corresponding author: Saber A. Sakr, Zoolgy Department, Faculty of Science, Menoufia University, Al Minufya, Egypt.
Tel: +20 10 0181 2099
E-mail: sabsak@yahoo.com

2.2. Histological and histochemical examination

From each representative paraffin block, multiple 4- μ m thick sections were cut and mounted on glass slides: One for routine hematoxylin and eosin (H&E) staining for histopathological examination to confirm the diagnosis and to evaluate the histopathological characteristics of tumor such as histopathological type (adenocarcinoma, mucoid carcinoma), histologic grade and pathologic stage according to TNM staging system, whereas stages T1 and T2 were lumped to represent early stage and T3 and T4 were lumped to be an advanced stage. Staging was also assessed according to original Dukes' staging system. Two slides for histochemical procedure. One to demonstrate DNA by modified Feulgen method[10]. DNA is stained deep-red purple. Other slides were used for demonstration of general carbohydrates by periodic acid Schiff's (PAS) technique[11]. PAS-positive material stained magenta color. PAS reactivity was divided into strong, moderate and low according to the concentration of the carbohydrates positive material in the tissue.

2.3. Counting of DNA cells

The slides were scanned at high magnification (1000 \times) in a definite area (9 \times 9 micron) from the field. Different types of DNA cells (pyknosis, mitosis and pleomorphism) were counted in 5 different fields then the mean was calculated and recorded. Pyknosis was defined by a condensation and reduction in the size of a cell or cell nucleus, usually associated with hyperchromatosis. The detention of mitosis is a process where a single cell and its nucleus divided resulting in generally two identical cells, each containing the same number of chromosomes and genetic content as that of the original cell. Variability in the size and shape of cells and/or their nuclei named as pleomorphism.

2.4. Statistical analysis

Results were collected, tabulated, statistically analyzed by IBM personal computer and statistical package SPSS version 11. Fisher exact and Mann-Whitney tests were used in comparison between qualitative and quantitative variables, respectively. *P*-value of < 0.05 was considered statistically significant.

3. Results

3.1. Clinicopathological data

3.1.1. Studied adenoma cases

The studied adenoma cases ($n = 10$) as shown in Table 1 were 60% males and 40% females with 1.5 as a male to female ratio. The age ranged between 36 and 70 years with a mean of (53.7 \pm 10.2) years and a median of 53 year. Fifty percent of adenoma cases were tubular type, 10% were villous type and 40% were tubulovillous.

Table 1

Clinical character of patients with adenoma.

Variables	No. (%)
Sex	
Male	6 (60)
Female	4 (40)
Age (year)	
Mean \pm SD	53.7 \pm 10.2
Median	53
Range	36–70
Type	
Tubular	5 (50)
Villous	1 (10)
Tubulovillous	4 (40)

3.1.2. Colorectal carcinoma cases

3.1.2.1. Clinical data

As shown in Table 2, 54.2% of CRC cases were males ($n = 26$) and 45.8% ($n = 22$) were females with 1.18:1 as a male to female ratio. Their age ranged between 21 and 70 years with a mean of 49.6 \pm 12.6 years and a median age of 51.5 year. CRC cases located in left side of colon represented 72.9% of cases whereas 27.1% were located in the right side. Tumors size ranged between 5 and 50 cm with a mean of (21.0 \pm 11.6) cm and a median of 20 cm.

Table 2

Clinical data of studied CRC cases.

Variables	No. (%)
Sex	
Male	26 (54.2%)
Female	22 (45.8%)
Age (year)	
Mean \pm SD	49.6 \pm 12.6
Median	51.5
Range	21–70
Site	
Right	13 (27.1%)
Left	35 (72.9%)

3.1.2.2. Pathological data

By histopathological examination of the CRC cases, 39 (81.25%) cases were adenocarcinoma and 9 (18.75%) cases were mucoid adenocarcinoma. Regarding the degree of differentiation, 2 (4.20%) CRC cases were well differentiated, 30 (62.50%) were moderately differentiated and 16 (33.30%) were poorly differentiated. According to Dukes' staging system, 5 (10.40%) CRC cases were stage A, 27 (56.30%) were stage B (B1 and B2), 14 (29.20%) were stage C (C1 and C2) and 2 cases (4.20%) were stage D. Concerning TNM staging system, most of cases 36 (75.00%) represented advanced stage (T3 and T4). Only 12 (25%) cases belonged to early staging (T1 and T2). Considering nodal status, 13 cases showed positive lymph node. The number of involved lymph nodes ranged between 0 and 7 with a mean of 1.03 \pm 1.7 and a median of 3 (Table 3).

Table 3

Pathological characteristics of CRC patients.

Variables	No. (%)
Type of tumor	
Adenocarcinoma	39 (81.25)
Mucinous adenocarcinoma	9 (18.75)
Grading	
I	2 (4.20)
II	30 (62.50)
III	16 (33.30)
Dukes' stage	
A	5 (10.40)
B (B1 & B2)	27 (56.30)
C (C1 & C2)	14 (29.20)
D	2 (4.20)
TNM stage	
T1	5 (10.40)
T2	7 (14.60)
Early (T1 & T2)	12 (25.00)
T3	25 (52.10)
T4	11 (22.90)
Advanced (T3 & T4)	36 (75.00)
Lymph node	
Negative	35 (72.90)
Positive	13 (27.10)
Lymph node	
Mean \pm SD	1.03 \pm 1.7
No.	
Median	3
Range	0–7

3.2. Histological results

The normal large intestine show four layers that make up to the

wall of the colon: the mucosa, the submucosa, the muscularis externa, and the serosa (Figure 1). The epithelial component of the mucosa is a mixture of an absorptive cell, and mucous cells. These are arranged as simple, straight, non-branching tubular downgrowths glands (crypts of lieberkuhn) Between the glands, is a lamina propria that contains considerable numbers of lymphocytes and other cells of immature systems. The submucosa consists of rather dense irregular connective tissue. It contains the larger blood vessels and areas of adipose tissue (Figure 2). The muscularis comprises longitudinal and circular strands. There are fibers in the outer longitudinal layer congregate in three thick longitudinal bands called teniae coli. In the interperitoneal portions of the colon, the serous layer is characterized by small, pendulous protuberances composed of adipose tissue.

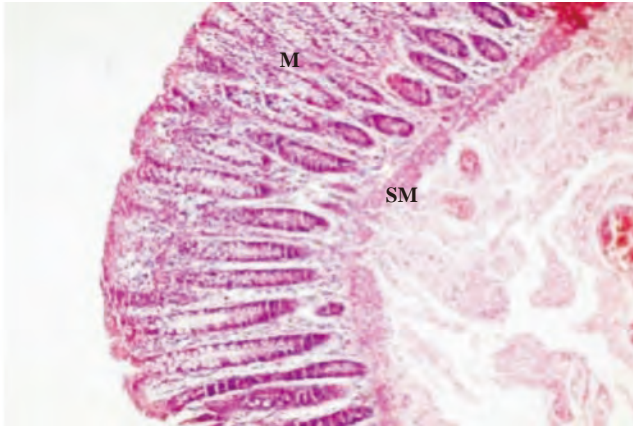


Figure 1. Section in the normal colon of the adjacent adenoma shows four layers that consists the wall of colon: mucosa, the submucosa (SM), the muscularis externa (M), and the serosa (H & E 100×).

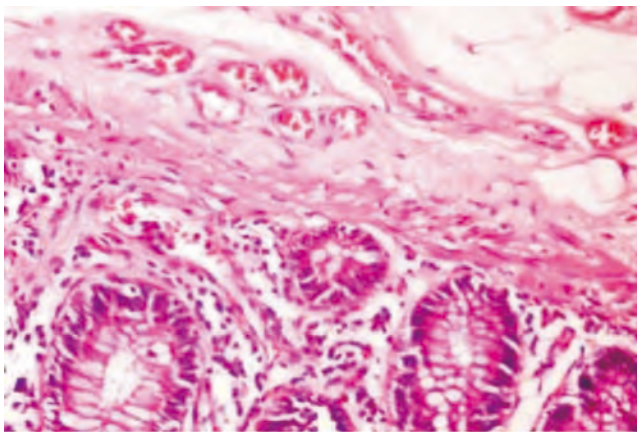


Figure 2. Section in normal colonic mucosa adjacent to adenoma showing the submucosa consists of rather dense irregular connective tissue. It contains the larger blood vessels and areas of adipose tissue (H & E 400×).

The studied adenoma cases showed tubular or villous structures lined by dysplastic epithelium. The crypts show architectural irregularities, being coiled, branched and crowded. Paneth cells and endocrine cells may be scattered haphazardly throughout the epithelium (Figure 3). Adenocarcinoma was divided according to the grade of the differentiation into well, moderately or poorly differentiated. Well differentiated adenocarcinoma comprise well formed glands with retain of the basal location (Figures 4 and 5). In moderately differentiated, the glands are less regular but remain easily recognized. Glands are highly irregular and difficult to discern in poorly differentiation. Mucooid adenocarcinoma cases demonstrated by mucus secreting epithelium (Figure 6).

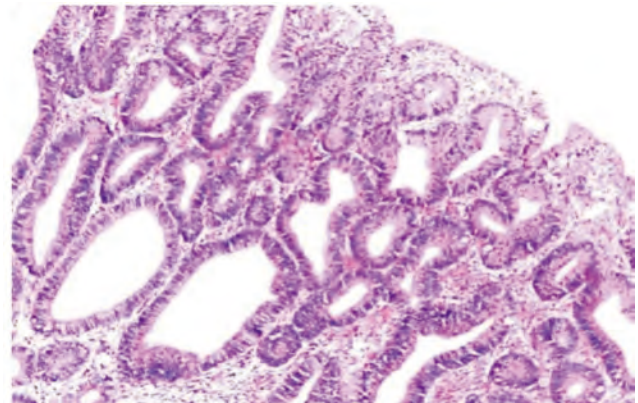


Figure 3. A case of tubular adenoma showing proliferating glands, some of them are cystically dilated and lined by dysplastic epithelial cells (H & E, 200×).

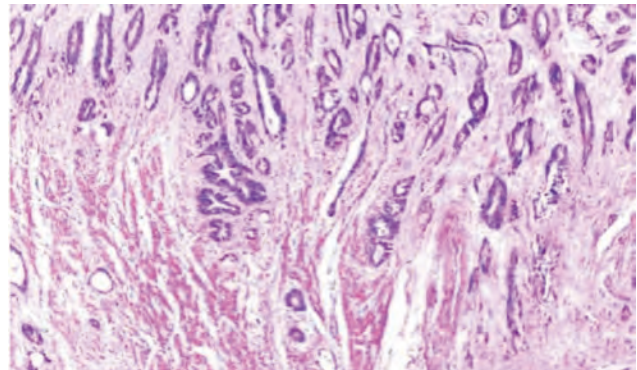


Figure 4. A case of well differentiated adenocarcinoma infiltrating muscle layer of colonic wall (H & E 100×).

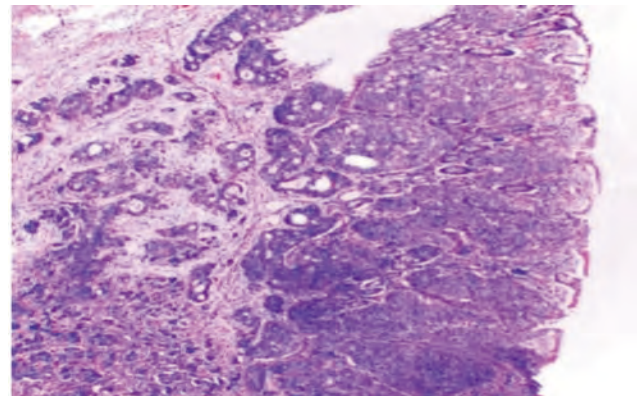


Figure 5. High grade adenocarcinoma formed mainly of solid sheets (H & E 100×).

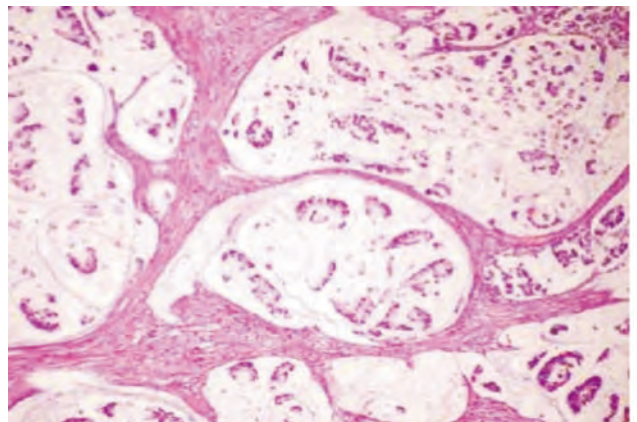


Figure 6. A case of mucooid adenocarcinoma characterized by mucin lakes with a malignant cells floating with mucin (H & E 200×).

3.3. Histochemical results

3.3.1. DNA

Using Feulgen reaction, the chromatin bodies of the normal cells adjacent to adenoma were stained red. The positive reaction obtained by these chromatin elements indicates the presence of DNA. The cytoplasm showed negative feulgen reaction indicating the non-existence of any detectable DNA inclusions. The chromatinic materials is distributed in the small round nuclei (Figure 7). Adenoma cases showed that the cells lining the glands of the polyp have more crowded, irregular and darker nuclei (hyperchromatic), anisonucleosis, abnormal mitotic figures with prominent nucleoli and variability in the size and shape of nuclei (Figures 8 and 9). The sections studied in colonic adenocarcinoma showed a condensation and reduction in the size of a cell nucleus associated with hyperchromatism, pyknotic nuclei, abnormal mitotic figures, anisonucleosis, irregular nuclear membrane and inequality in the size of the nuclei (pleomorphosis) (Figures 10 and 11). There was a statistical significant differences between adenoma and carcinoma regarding number of mitotic cells ($P = 0.03$) and DNA (Table 4) that was in favor of malignant group.

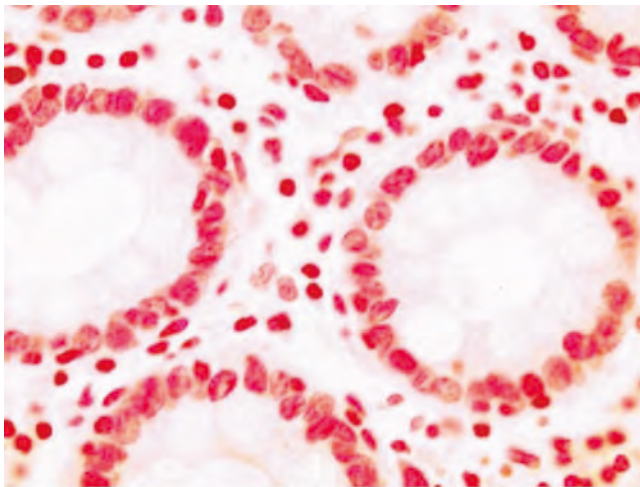


Figure 7. Section in the adjacent normal colonic mucosa of malignant case showing normal distribution of chromatinic materials in the small round nuclei (Feulgen, 1000×).

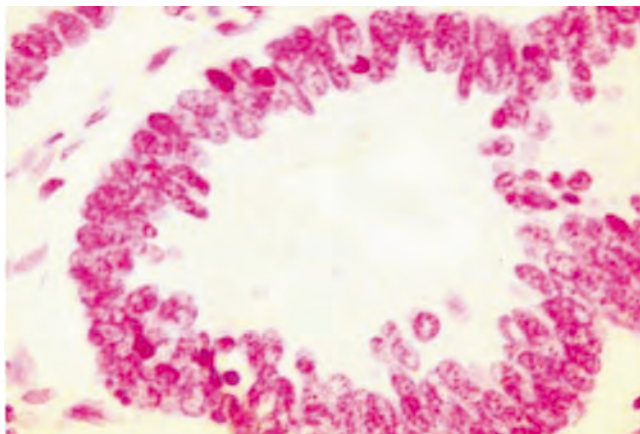


Figure 8. A case of adenoma showing that the cells lining the lands of the polyp have more crowded, irregular and darker nuclei (hyperchromatic) (Feulgen, 1000×).

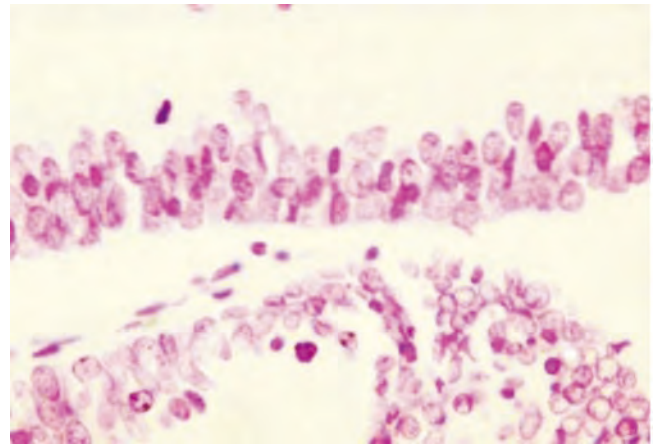


Figure 9. Section in colonic adenoma showing anisonucleosis and abnormal mitotic figures with prominent nucleoli (Feulgen, 1000×).

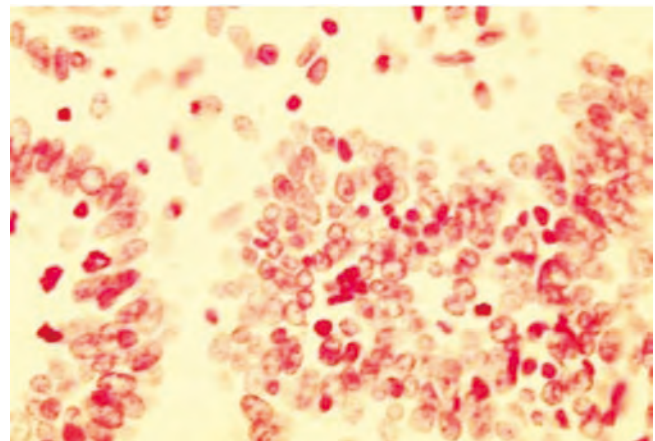


Figure 10. Section in colonic adenocarcinoma showing a condensation and reduction in the size of a cell nucleus associated with hyperchromatism (Feulgen, 1000×).

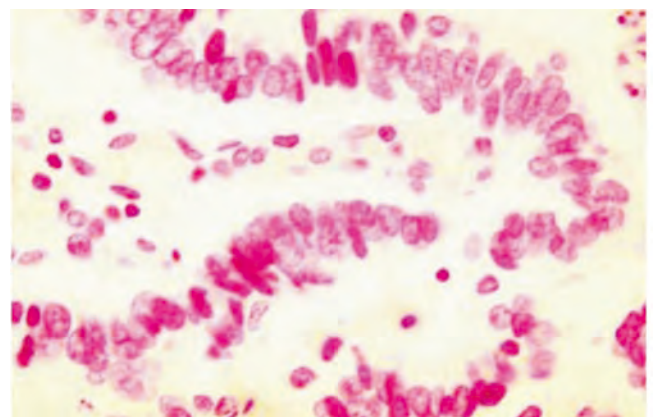


Figure 11. Another section in colonic adenocarcinoma showing pyknotic nuclei (Feulgen, 1000×).

Table 4

Differences between adenoma and carcinoma regarding DNA changes.

Variables	DNA pyknotic cells		DNA mitotic cells		DNA pleomorphic cells	
	Mean ± SD	Median Range	Mean± SD	Median Range	Mean ± SD	Median Range
Adenoma (n = 10)	6.25 ± 7.90	3 0-23	0.3 ± 0.5	0 0-1	20.3 ± 11.9	22 0-36
Malignancy (n = 48)	4.2 ± 8.1	2 0-38	1.06 ± 1.00	1 0-3	19.3 ± 8.0	20 0-32
U test	0.545		2.210		0.354	
P value	0.473		0.03*		0.724	

U: Mann-Whitney test; *: Significant.

3.3.2. Total carbohydrates

In the normal colon adjacent to adenoma, the total carbohydrates exist in the form of deeply stained reddish granules in the cytoplasm of the colonic cells as shown by PAS reaction. The nuclei of the colonic cells do not acquire any positive staining in non-counterstained preparations indicating the complete lack of glycogen (Figure 12). Examination of adenoma cases showed that the majority of cases demonstrated low PAS reaction (Figure 13) while the others demonstrated moderate PAS reaction (Figure 14). The stained slides of CRC cases revealed strong PAS reaction (Figure 15), moderate (Figure 16) and low reaction (Figure 17).

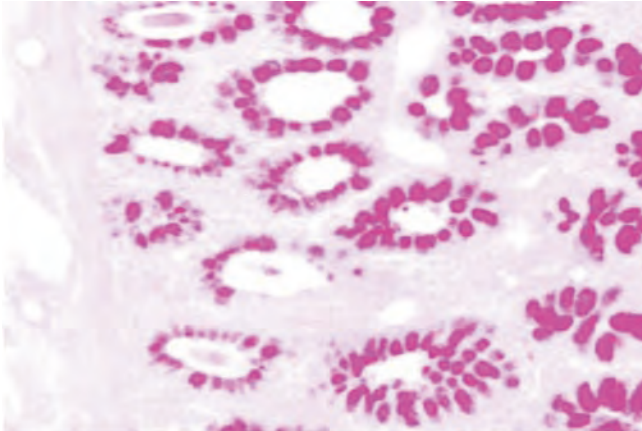


Figure 12. Section in the adjacent normal colonic glands of malignant case showing reddish goblet cells due to its mucus secretion (PAS, 200×).

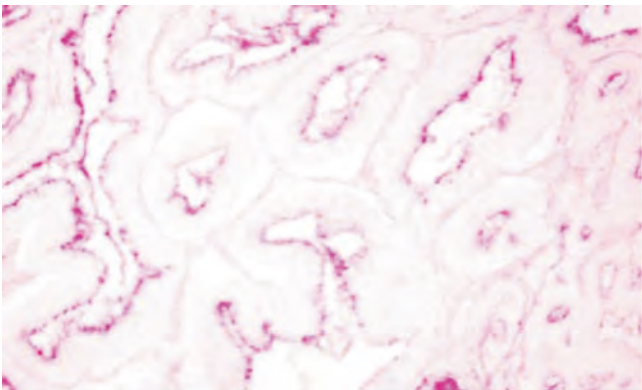


Figure 13. A case of tubular adenoma showing low PAS reaction (PAS, 400×).

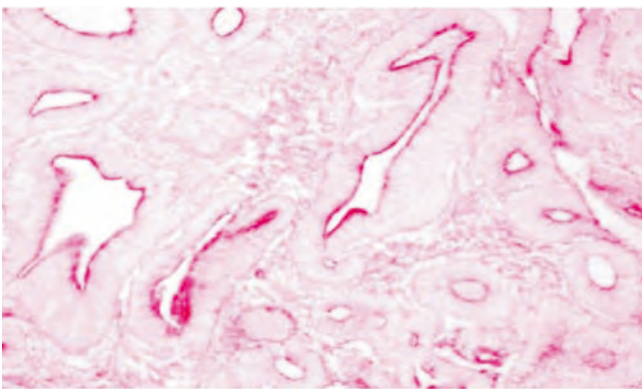


Figure 14. Section in tubulovillous adenoma showing moderate PAS reaction (PAS, 400×).

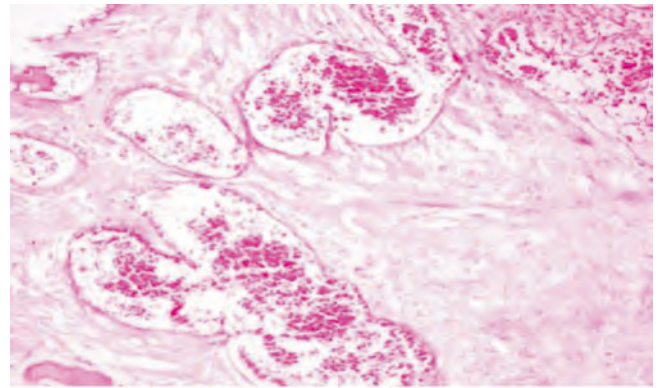


Figure 15. A case of mucoid adenocarcinoma showing strong PAS reaction in the cytoplasm of the malignant cells floating with mucin (PAS, 400×).

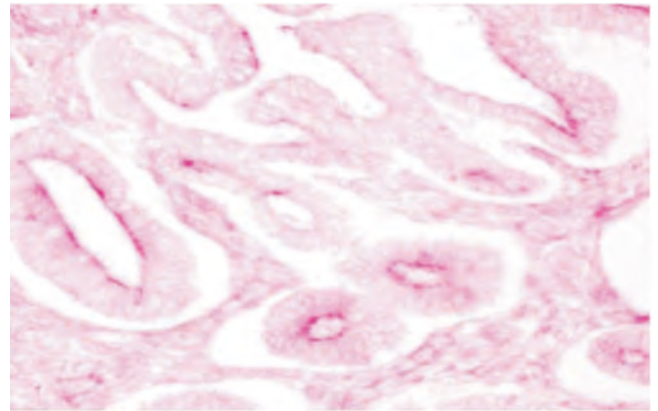


Figure 16. Section in a well differentiated colonic adenocarcinoma exhibits a moderate PAS reaction (PAS, 400×).

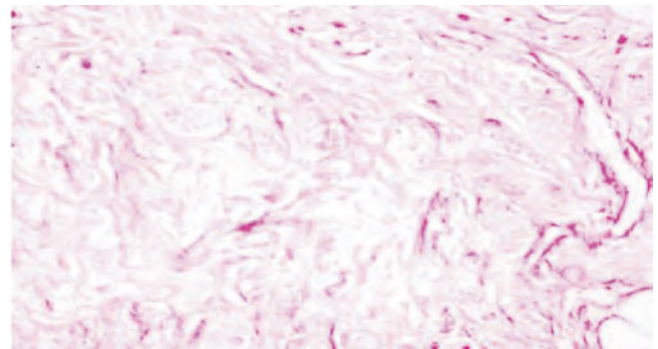


Figure 17. Section in high grade colonic adenocarcinoma showing low PAS reaction (PAS, 400×).

Statistical analysis revealed that adenoma cases didn't differ from carcinoma regarding PAS reaction (Table 5).

Table 5

Comparison between adenoma and malignancy regarding PAS reactivity.

Variables		Adenoma (n = 10)	Malignancy (n = 48)	χ^2 -test	P value
PAS Reactivity	Strong	0	8	16.7%	3.39
	Moderate	4	24	50%	
	Low	6	16	33.3%	

χ^2 : Chi-square test.

4. Discussion

In the present study, 10 adenoma cases were included in the study. The male to female ratio in adenoma cases was 1.5:1, this agreed with the fact that colorectal adenomas are more common in males[12]. The

age of adenoma cases ranged between 36 and 70 years with a median of 53 years. These results agreed with the study of Bas *et al.*[13]. They reported that the mean age of adenoma cases was 53.8 years with male predominance. Regarding the type of adenoma, tubular type was the commonest (50%) followed by tubulovillous one (40%) then villous type (10%). Similarly, Gentiana *et al.*[14] stated that tubular adenoma is the most common type.

In this study, regarding CRC cases, 54.2% were males and 45.8% were females with 1.18:1 as a male to female ratio. The reasons are not completely understood, but likely reflect complex interactions between gender-related differences in exposure to hormones and risk factors[15]. The high male affection by CRC agreed with Egyptian[4] and Western studies that also showed higher mortality in men[15]. Concerning the age of CRC cases, it ranged between 21 and 70 with a median of 51.2 years, agreeing with El-Badry *et al.*[16] who illustrated that the age of CRC cases ranged between 20 and 86 years with a mean age of 56.6 years in Egyptian patients.

In this work, CRC cases arising in the left side of colon represented 72.9% of cases whereas 27.1% were located in the right side. According to Gado *et al.*[17] 53% of Egyptian CRC patients were located in the left colon (sigmoid colon, descending colon and splenic flexure), 16% in the rectum and 32% were located in the proximal colon (cecum, ascending colon, hepatic flexure and transverse colon). Smyrk[18] also illustrated that cancers of the left colon outnumbered those of the right ones. According to Abou-Zeid *et al.*[6], 75% of CRC in Egypt, also occurred in the left side.

Histopathological examination in this work revealed that adenocarcinoma was the most common histopathologic type of tumors representing 81.25% of cases while 18.75% of cases were mucoid adenocarcinoma. The majority of cases were grade II (62.5%) followed by grade III (16%) then grade I (4.2%). Veruttipong *et al.*[3] studied the clinical and histopathological characteristics of CRC patients in Egypt and also found that the grade II was predominant (51.5% of cases) followed by grade III (11.4%).

Concerning TNM staging system, most of cases [36 (75%)] represented advanced stage (T3 and T4). Only 12 (25%) cases belonged to early staging (T1 and T2). These results agreed with Sharaf *et al.*[19] who reported that the most prevalent tumor stage of Egyptian cases belonged to advanced stage T3 (right 88.6%, left 79.7%).

Tumorigenesis appears as a multistep process not only in molecular terms but also in morphological alterations[10]. Among the observed morphological changes in tumor cells are alterations of nuclear structure. These include changes in nuclear size and shape, numbers and sizes of nucleoli, and in 'chromatin texture'. These alterations can be so characteristic of a given tumor type and stage that they are used in cancer diagnosis and might also be related to the altered functional properties of cancer cells[9]. DNA index, shape factor, the widest diameter and density of nuclei were demonstrated to be the valuable parameters in Feulgen-stained sections[20]. These changes were highlighted in the present work by histochemical demonstration of DNA changes in tumor cells.

Patients with adenoma showed nuclear alternations that were characterized by hyperchromatic, elongated nuclei, anisonucleosis and abnormal mitotic figures with prominent nucleoli. These results were supported by the study of Rubio[21] who studied qualitative DNA in colorectal adenomas. High grade dysplasia areas showed tightly packed, spindle shaped, hyperchromatic cells with slight to moderate pleomorphic nuclei having coarse chromatin. The carcinoma in situ cells displayed marked pleomorphism and large vesicular (oval or round-shaped) nuclei. The nucleolus was prominent and irregular. The

nuclear membrane was often notched.

Another study by Whitehead *et al.*[22] about the ploidy in adenomatous polyps of the colon. They found some dysplastic changes such as variation in nuclear size, shape, and optical density which reflect the important changes in the replication, differentiation, and function of the cell. There were also nuclei with a hyperdiploid DNA constitution. These hyperdiploid DNA values were perhaps caused by the defective division of the nucleus during mitosis producing an unequal share of DNA between the two daughter cells. Steinbeck[23] reported that the chromosome division figures were found in all cases of high grade dysplasia and it considered to be the first morphological manifestation of genomic instability attending precancerous conditions in the colon.

In CRC cases, there was alteration in the architecture of nuclei such as inequality in the size (pleomorphism), abnormal mitotic figures, anisonucleosis, irregular nuclear membrane and changes in chromatinic content (Pyknosis). In this concern, Staarmann *et al.*[24] studied DNA ploidy and morphology of colon tumors in the adenoma-carcinoma sequence using Feulgen stain. They resulted that the size of tumor nuclei and mitoses usually reflects the ploidy level of colon tumors and demonstrated a considerable variation in the DNA content (hyperdiploid) in all stages of carcinoma. Also, Deans *et al.*[25] studied DNA densitometry of CRC and demonstrated that because DNA aneuploidy represents increased amounts of nuclear DNA, aneuploid tumours might have larger nuclear areas.

In this study, histochemical reaction for the adjacent normal colonic mucosa cases showed that the total carbohydrates exist in the form of deeply stained reddish granules in the cytoplasm while the nuclei of the colonic cells do not acquire any positive staining. These results were shown by some studies[26,27]. They revealed that seven genes for the protein component of epithelial mucins have been cloned. Of these, MUC2, MUC3 and MUC4 are expressed by intestinal goblet cells so it would seem reasonable to assume that the normal counterpart of secretory material within CRCs is goblet cell mucin. Also, Ajioka *et al.*[28] reported that MUC2 expression within normal colon showing restriction of expression to the perinuclear cytoplasm of goblet cells.

The adenoma cases showed moderate and low PAS reaction. Adenocarcinoma showed low or weak reaction while mucoid carcinoma showed strong reactivity. MUC2 was reported to be expressed by adenomas and mucinous carcinomas with its down regulation in non mucinous adenocarcinomas[29]. Furthermore, it was previously reported that MUC1 and MUC2 expression could be related to specific cell lineages within CRC, namely columnar cells and goblet cells, respectively[30]. Mucin like material within CRC would therefore comprise MUC1, MUC2 or mixtures of both depending on lineage of differentiation. It was further predicted that particular carbohydrate structures might be co-expressed with MUC1 and MUC2 and that these would show characteristic patterns of localization[30]. Also, Blank *et al.*[29] added that the hypersecretion of all mucin species (perhaps including MUC3 and MUC4) is a characteristic of mucinous carcinoma.

The malignant process may result in an unusual increase of glycogen storage. In general, Cellular energy metabolism is one of the main processes that is affected during the transition from normal to cancer cells. In particular, glucose metabolism is very often altered in tumor cells[31]. Rousset *et al.*[32] measured the glycogen contents during the exponential phase of growth of 58 human tumor cell lines, most of them originating from tissues with low glycogen storage. Glycogen was presented in all cell lines and its levels in the different cell lines were generally independent on their tissue origin. The authors also studied the kinetics of glycogen storage in relation to the process of cell growth

in five cell lines including the carcinoma of urinary bladder. There was a plateau of the basal glycogen level during the exponential phase of growth, followed by a regular increase in glycogen accumulation as cell division started to slow down, reaching maximum levels when the cells come into arrest of growth.

The activities of glycogen synthase and glycogen phosphorylase (key enzymes implicated in regulation of glycogen metabolism) were measured and compared to the growth-related variations of glycogen accumulation in three cultured human tumor cell line by Rousset *et al.*[33]. The authors observed that both the enzymes are present in the three cancer cells studied. The pattern of these enzyme activities as a function of the pattern of glycogen accumulation during cell growth suggested, however, that the mechanism(s) of control of glycogen synthesis in these cancer cells is different from the normal cells.

Conflict of interest statement

The authors declare that there is no conflict of interest .

Acknowledgments

Authors are thankful to Faculty of Science and Faculty of Medicine, Menoufia University, Egypt for providing laboratory facilities and instruments to carry out this work.

References

- [1] Hagggar FA, Boushey RP. Colorectal cancer epidemiology: incidence, mortality, survival, and risk factors. *Clin Colon Rectal Surg* 2009; **22**(4): 191-7.
- [2] Zahir MN, Azhar EM, Rafiq S, Ghias K, Shabbir-Moosajee M. Clinical features and outcome of sporadic colorectal carcinoma in young patients: a cross-sectional analysis from a developing country. *ISRN Oncol* 2014; doi: 10.1155/2014/461570.
- [3] Veruttipong D, Soliman AS, Gilbert SF, Blachley TS, Hablas A, Ramadan M, et al. Age distribution, polyps and rectal cancer in the Egyptian population-based cancer registry. *World J Gastroenterol* 2012; **18**(30): 3997-4003.
- [4] Zeeneldin AA, Saber MM, Seif El-din IA, Frag SA. Colorectal carcinoma in gharbiah district, Egypt: comparison between the elderly and non-elderly. *J Solid Tumor* 2012; **2**(3): 13-23.
- [5] Elbaz T, Esmat G. Hepatic and intestinal schistosomiasis: review. *J Adv Res* 2013; **4**(5): 445-52.
- [6] Abou-Zeid AA, Khafagy W, Marzouk DM, Alaa A, Mostafa I, Ela MA. Colorectal cancer in Egypt. *Dis Colon Rectum* 2002; **45**(9): 1255-60.
- [7] Stewart BW, Kleihues P. Colorectal cancer. In: Stewart BW, Kleihues P, editors. *World cancer report*. Lyon: IARC press; 2003, p. 198-202.
- [8] Damania D, Subramanian H, Backman V, Anderson EC, Wong MH, McCarty OJ, et al. Network signatures of nuclear and cytoplasmic density alterations in a model of pre and postmetastatic colorectal cancer. *J Biomed Opt* 2014; **19**(1): 1-11.
- [9] Zink D, Fischer AH, Nickerson JA. Nuclear structure in cancer cells. *Nat Rev Cancer* 2004; **4**(9): 677-87.
- [10] Lillie RD, Fulmer HM. *Histopathologic technique and practical histochemistry*. 4th ed. New York: McGraw Hill; 1976.
- [11] Hotchkiss RD. A microchemical reaction resulting in the staining of polysaccharide structures in fixed tissue preparation. *Arch Biochem* 1948; **16**: 131-41.
- [12] Kunjumon DT, Glaxon JA, Pai KP. A histopathological study of 23 cases of benign epithelial polyps of intestine. *Int J Biomed Res* 2014; **5**(2): 117-20.
- [13] Bas B, Dinc B, Oymaci E, Mayir B, Gunduz UR. What are the endoscopic and pathological characteristics of colorectal polyps? *Asian Pac J Cancer Prev* 2015; **16**(13): 5163-7.
- [14] Gentiana C, Altin C, Arben B, Mehdi A. Histopathological characteristics of colon polyps—a population-based study in Tirana, Albania. *J Gastrointest Dig Syst* 2015; doi: 10.4172/2161-069X.1000271.
- [15] Murphy G, Devesa SS, Cross AJ, Inskip PD, McGlynn KA, Cook MB. Sex disparities colorectal cancer incidence by anatomic subsite, race and age. *Int J Cancer* 2010; **128**(7): 1668-75.
- [16] El-Badry AI, Abdalla MN, Aref WM, Kamel MH, Ishak EA, Farah BSH. Prevalence of colonic polyps among Egyptians, retrospective study. *J Am Sci* 2012; **8**(11): 394-6.
- [17] Gado A, Ebeid B, Abdelmohsen A, Anthony A. Colorectal cancer in Egypt is commoner in young people: is this cause for alarm? *Alexandria J Med* 2014; **50**(3): 197-201.
- [18] Smyrk TC. Colorectal cancer pathology In: *Gastrointestinal oncology principals and practice*. Philadelphia: Lippincott Williams & Wilkins; 2002, p. 717-30.
- [19] Sharaf WM, Esmail RSE, Farrag ARH, Omara EA, Helmy NA, Shaffie NM. The relevance of Ki-67 and COX-2 immunoexpression in right-sided versus left-sided sporadic cancer colon in Egyptian patients. *Arab Soc Med Res* 2014; **9**(2): 75-80.
- [20] Jin W, Gao MQ, Lin ZW, Yang DX. Multiple biomarkers of colorectal tumor in a differential diagnosis model: a quantitative study. *World J Gastroenterol* 2004; **10**(3): 439-42.
- [21] Rubio CA. Qualitative DNA differences between two structurally different lesions: high-grade dysplasia and carcinoma in situ in colorectal adenomas. *Anticancer Res* 2007; **27**(4C): 2881-5.
- [22] Whitehead F, Jarvis LR, Skinner JM, Whitehead R. Ploidy studies in adenomatous polyps of the colon. *J Clin Pathol* 1985; **38**(11): 1261-4.
- [23] Steinbeck RG. Chromosome division figures reveal genomic instability in tumorigenesis of human colon mucosa. *Br J Cancer* 1998; **77**(7): 1027-33.
- [24] Staarmann J, Kotb WF, Petersen I. DNA ploidy and morphology of colon tumors in the adenoma-carcinoma sequence. *Folia Histochem Cytobiol* 2015; **53**(1): 11-8.
- [25] Deans GT, Williamson K, Hamilton P, Heatley M, Arthurs K, Patterson CC, et al. DNA densitometry of colorectal cancer. *Gut* 1993; **34**(11): 1566-71.
- [26] Chang SK, Dohrman AF, Basbaum CB, Ho SB, Tsuda T, Toribara NW, et al. Localization of mucin (MUC2 and MUC3) messenger RNA and peptide expression in human normal intestine and colon cancer. *Gastroenterology* 1994; **107**(1): 28-36.
- [27] Jass JR, Robertson AM. Colorectal mucin histochemistry in health and disease: a critical review. *Pathol Int* 1994; **44**: 487-504.
- [28] Ajioka Y, Allison LJ, Jass JR. Significance of MUC1 and MUC2 mucin expression in colorectal cancer. *J Clin Pathol* 1996; **49**(7): 560-4.
- [29] Blank M, Klussmann E, Kruger-Krasagakes S, Schmitt-Graff A, Stolte M, Bornhoeft G, et al. Expression of MUC2-mucin in colorectal adenomas and carcinoma of different histological types. *Int J Cancer* 1994; **59**(3): 301-6.
- [30] Jass JR, Allison LJ, Edgar SG. Distribution of sialosyl Tn and Tn antigens within normal and malignant colorectal epithelium. *J Pathol* 1995; **176**: 143-9.
- [31] Annibaldi A, Widmann C. Glucose metabolism in cancer cells. *Curr Opin Clin Nutr Metab Care* 2010; **13**(4): 466-70.
- [32] Rousset M, Zweibaum A, Fogh J. Presence of glycogen and growth-related variations in 58 cultured human tumor cell lines of various tissue origins. *Cancer Res* 1981; **41**(3): 1165-70.
- [33] Rousset M, Paris H, Chevalier G, Terrain B, Murat JC, Zweibaum A. Growth-related enzymatic control of glycogen metabolism in cultured human tumor cells. *Cancer Res* 1984; **44**(1): 154-60.