

Management of Limited Interocclusal Space Using Castableabutment - A Clinical Case

Received: 18 February 2023, **Revised:** 26 March 2023, **Accepted:** 28 April 2023

¹Dr. Pardeep Bansal, ²Dr. Preetika Bansal, ³Dr. Kannupriya Aggarwal, ⁴Dr. Rithika Elsa George, ⁵Dr. Prabjeet Kaur

1Professor and Head, 3,4,5Post-Graduate, Department of Prosthodontics, Dasmesh Institute of Research and Dental Sciences, Faridkot, Punjab, India

2Professor, Department of Periodontics, Dasmesh Institute of Research and Dental Sciences, Faridkot, Punjab, India

Corresponding Author: Dr. Pardeep Bansal,

Professor and Head, Department of Prosthodontics, Dasmesh Institute of Research and Dental Sciences, Faridkot, Punjab, India Email: drpardeepbansal77@gmail.com

Keywords:

UCLA; Screw Retained; Cement Retained; Aesthetics; Retrievability; Inadequate Interocclusal Space.

Abstract

The choice of either cement or screw to retain the prosthesis depends on the clinician's preference. Both treatment modalities have their advantages and disadvantages. Cement retained has better aesthetics and low cost however screw-retained prosthesis preserves gingival health and is retrievable that is achieved without damaging the restoration or any implant component. This case report presents a case with the replacement of a mandibular molar due to inadequate interocclusal distance for cement-retained prosthesis and the situation was managed with screw-retained UCLA abutment.

1. Introduction

Single-tooth implant restorations have become a crucial part of the prosthodontic rehabilitation of partially edentulous patients. The prostheses can be fixed to implants either with screws or through cementation². The choice of retention in implant-supported prosthetic restorations has an impact on the final occlusal design and is a complex decision involving many points of consideration.

There are various other treatment options other than implants such as

- A Conventional Removable Partial Denture
- Cast Partial Dentures
- Fixed Partial Dentures
- Resin Bonded Fixed Partial Prosthesis
- Essix Appliance

But using the conventional partial dentures can be very tiering at times as it compromises aesthetics and is uncomfortable to the patient. Also, cast partial dentures shows metallic part which is highly unesthetic and requires considerable tooth preparation of the abutment teeth. Essix appliance is usually

avoided because the long use of this appliance causes rapid wear. It is usually recommended as provisional restoration and it has poor color stability³. Using Conventional fixed partial dentures is also not recommended because it requires extensive preparation of the adjoining tooth which is not conservative. Resin-bonded fixed partial dentures like Maryland Bridge prosthesis can be used in clinics but a fully erupted teeth is required for sufficient enamel to retain the prosthesis also, its retention depends upon the compressive strength of the metal to be used and is contraindicated for long-term use. The use of dental implants is universally accepted and is treatment of choice as it is more conservative and aesthetic to replace missing tooth structure. It is well-documented in research that various factors influence the amount of retention, whether they exist on natural tooth or implant abutments are taper or parallelism, total surface area, and height, surface finish or roughness, and type of luting cement used.

The 5-year survival rates of cement and screw-retained restorations are 96.03% and 95.55%, respectively. A fastening screw provides the stout joint between the restoration and the abutment in screw-retained restorations. The screw-retained implant

reconstruction is more advantageous as compared to the cement retained as it achieves better contours of the tissues, its health, and soft tissue transfer. Studies have revealed that prosthesis can be simplified using screw-retained implantation because of the ease of retrievability. Also, in clinical situations with a reduced interocclusal space, a screw-retained implant restoration is a usual choice. As, it permits better hygiene of the implants and the surrounding mucosa. The major problem with screw-retained restorations is a lack of versatility in design and suffer from inherent mechanical strength. The presence of an occlusal channel for screw access breaks the porcelain continuity and diminishes the fracture resistance of the porcelain.

2. Case Report:

A 37-year-old female patient reported in the department of prosthodontics at Dasmesh Dental College with the chief complaint of difficulty in chewing food due to missing teeth. Upon intra-oral examination, the left mandibular first molar was found to be missing. It was observed that the patient had limited interocclusal space of less than 5mm as shown in Figure 1. However, the mesiodistal width and buccolingual width were adequate. So, it was decided to go with a screw-retained prosthesis. No relevant dental and medical history was reported.

A Dentium super line implant (4.5*13 mm; Superline™, dentium USA, Cypress, CA, USA) was placed under aseptic protocol into the prepared site with an insertion torque of 35 Ncm to gain primary stability. The cover screw was placed, flaps were approximated and 3'o Mersilk was used to suture the surgical site. Postoperatively, Digital Radiovisography (RVG) of implant placement was evaluated. Standard postoperative instructions were given to the patient. Patients were evaluated after 10 days to assess the

implant site for wound healing and suture removal. After 3 months of the healing period the second-stage surgery was carried out, in which the cover screw was replaced with the healing cap.

After 1 week of placement of the healing cap, there was the formation of a gingival collar as shown in fig. 2. The implant impression procedure was carried out. A stock tray was used to make a closed tray master impression. The healing cap was removed and the closed tray impression coping was positioned on implant surface. An implant level impression was made with polyvinyl siloxane (Aquasil Light Body, Dentsply, Milford, DE, USA) using putty wash technique (fig. 3) and maxillary impression was made using alginate (Dentsply Zelgan, USA). After disinfecting the impression with 2% of glutaraldehyde (Cidex, India). Impression coping and implant analog assembly was positioned into the impression & the snug fit of coping in the impression was assessed. Then soft gingi-mask (Premier Dent International, India) was injected around it. Finally, the impression was poured with type IV gypsum product (kalabhai dental Pvt. Ltd, India). The casts were articulated on semi-adjustable articulator. Metal castable abutment (with hex) was taken & wax pattern with inlay pattern was fabricated after adjusting the occlusal height. The casting was done in Ni-Cr alloy in conventional manner. Once the metal try-in was done in patients' mouth after finishing the casting. The shade selection was done using the vita shade guide (Vita System 3d-Master). Ceramic layering was done (Vita, Vmk 95), glazing and polishing was done after a bisque trial. The occlusion was checked & then the crown was torqued to its final prosthesis in mouth at 30Ncm using the torque ratchet. The access of abutment screw was blocked with Teflon tape and access was blocked with glass ionomer cement (GC Gold Label 1). The patient was counselled for maintenance and routine follow up visits.

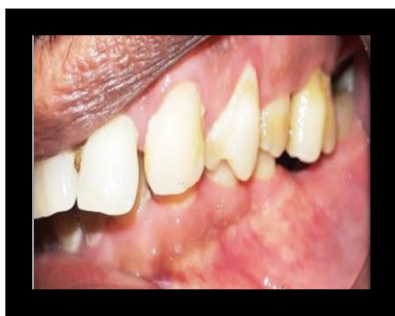

Figure 1- Patient With Limited Interocclusal Space

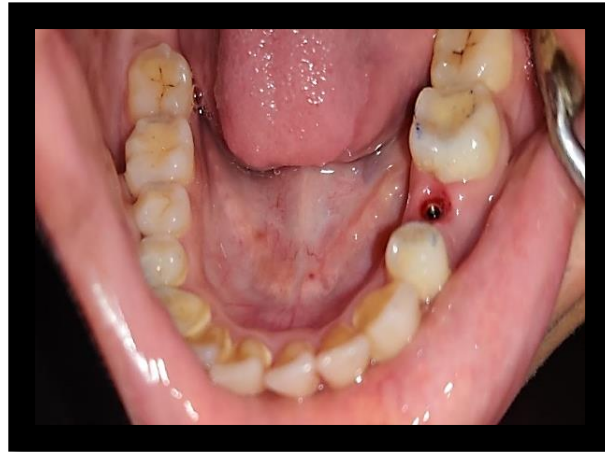


Figure 2 Gingival Collar Formation



Figure 3 Impression Made With Addition Silicone (Putty And Light Body Consistency) And Gingival Mask Applied

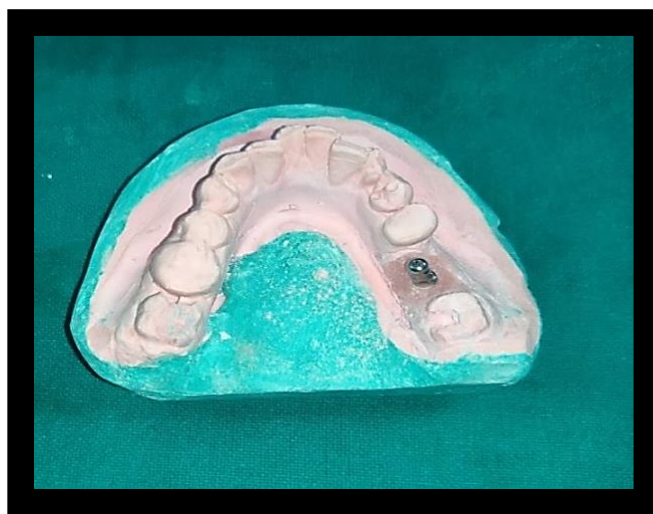

Figure 4- MastercastRetrived With Impression Coping.




Figure 5 Wax Pattern For Metal Ceramic Crown.

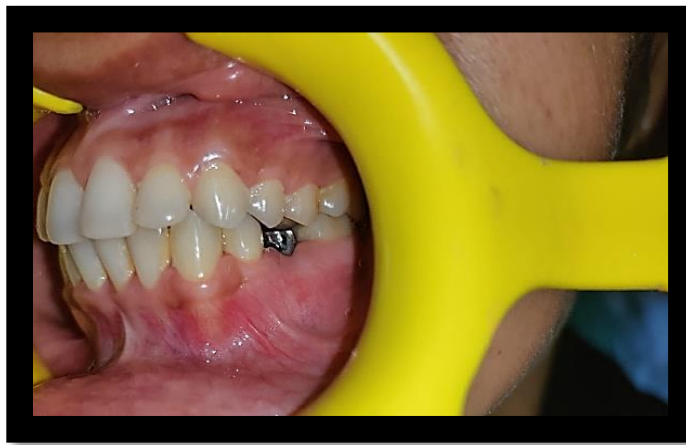

Figure 6- Metal Try- In Verification In Patients Mouth

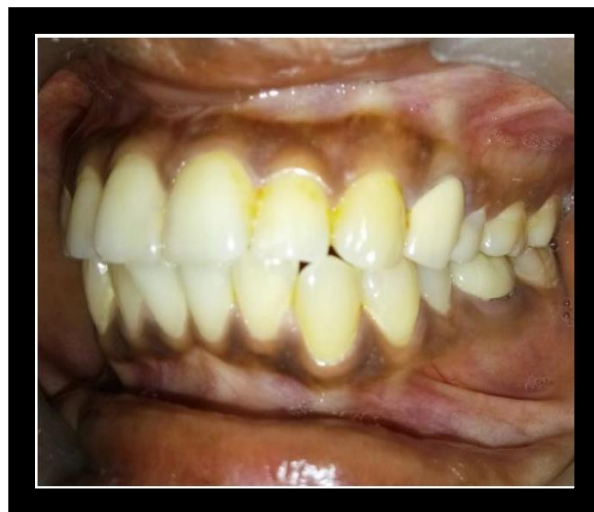

Figure 7- Porcelain Fused Metal Crown Fabrication and Evaluated Intraorally.

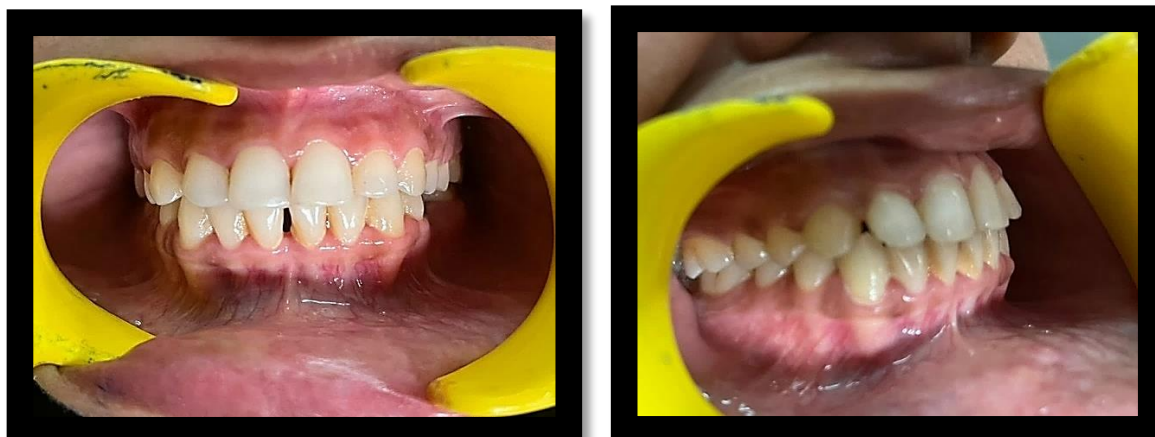

Figure 8- Occlusion After Screwing The Final Prosthesis.

3. Discussion

An implant consists of three parts- the Fixture, an Abutment which is an intermediate between the crown and fixture, and the Prosthesis. According to GPT-9 -A dental abutment is defined as a part of a structure that directly receives pressure or thrust. It is the tooth, a part of a tooth, or that portion of an implant that retains a prosthesis⁸. These abutments can be of types such as prefabricated or customized abutments, with internal or external connection, cement or screw retained abutment.

The unique designing for the UCLA abutment was a plastic burnout pattern. This pattern has a feature such as a 0.5mm shoulder, a larger screw access hole for a center screw, and a short-length collar gingivally. The customized wax pattern with inlay wax around the castable abutment develops the contour for the metal substructure of the crown according to the individual and then invest the wax pattern and cast it.

For the present case, hex castable abutment was used because, during the replacement of a single crown, there is a common problem encountered i.e rotation of the crown. Usually, non-hex abutments are prone to abutment screw loosening and rotation of the single crown because of the absence of anti-rotational grooves. The constrained engagement of the external member and the presence of a short fulcrum point whilst tipping forces act, is the principal cause of abutment screw loosening in external hex connections. Whereas the hex abutment has an anti-rotational mechanism. Hence it is always preferred over non hex abutments.

For the present case screw retained prosthesis was choice of prosthesis. Even though Cement retained implant prostheses are easy to fabricate, provide superior esthetics and optimal occlusal design whereas screw-retained prostheses are more advantageous as they are easy to retrieve, protect gingival health as no cement is used, and are easy to maintain the overall oral hygiene. When interarch occlusal space is limited, clinicians tend to avoid cement-retained prostheses because over reduction of the abutment would mean less retention which is an absolute contraindication especially in area with heavy masticatory forces. Hence screw retained abutment is the choice of prosthesis for such cases with internal hex connection

4. Conclusion

Implant prosthesis can be retained by either screw-retained or cement-retained prosthesis. Using a screw-retained prosthesis helps in the easy retrievability of the prosthesis. Conversely, it is a little tricky because of screw loosening due to biomechanical overloading. To avoid this problem regular follow-ups are required. UCLA abutments can be the best treatment for patients with limited interarch gap. Adequate treatment planning, knowledge of the occlusal scheme of the individual tooth along with tightening the prosthesis to the accurate torque, and regular recall appointments will help to minimize the frequency of abutment screw loosening and fracture.

Bibliography

- [1] Misch CE. "The importance of dental implants". General Dentistry 49 (2001): 38-45.

Journal of Coastal Life Medicine

- [2] Assaf, M. and Alaa'Z, A.G., 2014. Screw-retained crown restorations of single implants: A step-by-step clinical guide. *European journal of dentistry*, 8(04), pp.563-570.
- [3] Chopra, S., Bansal, P. and Bansal, P., 2020. Essix Appliance: An Innovation Modification for use as Temporary Bridge-A Case Report. *Journal of Advanced Medical and Dental Sciences Research*, 8(1), p.184.
- [4] Van Staden, R.C., Guan, H., Loo, Y.C. and Johnson, N.W., 2008. Comparative analysis of internal and external-hex crown connection systems-a finite element study. *Journal of Biomedical Science and Engineering*, 1(01), p.10.
- [5] Goiato, M.C., Sônego, M.V., da Silva, E.V.F., de CarvalhoDekon, S.F., de Medeiros, R.A., de Carvalho, K.H.T. and Dos Santos, D.M., 2015. Dynamic UCLA for single tilted implant in an aesthetic region. *International Journal of Surgery Case Reports*, 7, pp.149-153.
- [6] Kalpana, D., Rao, S.J., Pathi, V., Joseph, J.K. and Parween, N., 2018. Management of insufficient crown height space with UCLA abutments.
- [7] Krishnan, V., Tony Thomas, C. and Sabu, I., 2014. Management of abutment screw loosening: Review of literature and report of a case. *The Journal of Indian Prosthodontic Society*, 14(3), pp.208-214.
- [8] Hickey, J.C., 1968. Glossary of prosthodontic terms. *The Journal of prosthetic dentistry*, 20(5), pp.443-480.
- [9] Hebel, K.S. and Gajjar, R.C., 1997. Cement-retained versus screw-retained implant restorations: achieving optimal occlusion and esthetics in implant dentistry. *The Journal of prosthetic dentistry*, 77(1), pp.28-35.